

# **Multidisciplinary treatment of complicated subgingivally fractured permanent central incisor- A Case Report**

**Sumedh S. Khare \* Ruchi Arora\*\* Vineet Dhar\*\*\***

\*M.D.S. \*\*M.D.S, Professor & Head, \*\*\*M.D.S, Ph.D,  
Professor, Department of Pedodontics, Darshan Dental  
College, Udaipur, Rajasthan, India. Contact:  
sumedh.khare@yahoo.com

## **Abstract**

Subgingival crown fracture with pulp exposure in permanent teeth is a challenging task for a dental practitioner both from endodontic and restorative point of view.

Reattachment of original tooth fragment should be a first choice of treatment provided the fractured fragment is available in appropriate condition.

This clinical case report describes the fragment reattachment of complicated subgingivally fractured anterior tooth of a nine year old boy. Factors of clinical importance related to such treatment modality at this age are also briefly discussed.

**Keywords:** Reattachment, Fractured fragment, flowable compomer.

## **Introduction:**

Fracture of anterior teeth in young children is a miserable experience and can make the child depressed. The reattachment of fragment in case of fractured tooth should be the first choice of treatment if the fractured fragment is available and usable. Coronal fracture by trauma has been reported to account for up to 92% of all traumatic injuries to permanent dentition.<sup>1</sup> Most of the affected teeth are maxillary incisors (80% central incisors and 16% lateral incisors) due to

*P- ISSN*  
*0976 – 7428*

*E- ISSN*  
*0976 – 1799*

*Journal of  
International  
Oral Health*

Pedodontics

Case Report

*Received: July, 2010*

*Accepted: Oct, 2010*

## **Bibliographic listing:**

EBSCO Publishing

Database, Index

Copernicus, Genamics

Journalseek Database

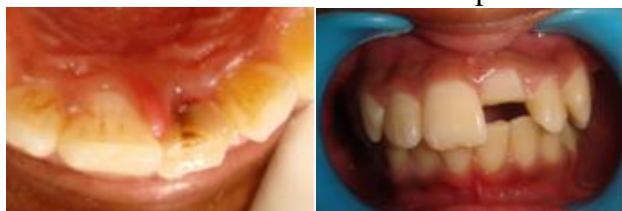their anterior position and protrusion caused by the eruptive process.<sup>1, 2.</sup> Tennery<sup>3</sup>, Starkey<sup>4</sup> and Simonsen<sup>5</sup> were the early workers to report the cases of “tooth fragment reattachment”. The development of adhesive material has provided new perspective in the treatment of fractured teeth. Tooth fragment reattachment technique represents an important step in the science and art of restoring fractured anterior teeth. Fragment bonding usually restores the incisal function and surface anatomy perfectly<sup>7</sup> and is probably less traumatic, simple and low cost method. Additionally it establishes superior esthetics, positive emotional and social response from the patient towards the preservation of natural tooth structure.<sup>6</sup>

The present case report describes the multidisciplinary treatment of complicated subgingivally fractured permanent central incisor.

#### Case report:

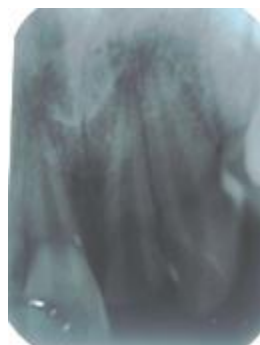A nine year old boy reported to the Department of Pedodontics and Preventive Dentistry, Darshan Dental College, Udaipur, India with the trauma to anterior tooth.

The patient’s medical history revealed no contributory factors. The trauma had occurred 15 days back due to fall while working in the farm and that no treatment had been performed.

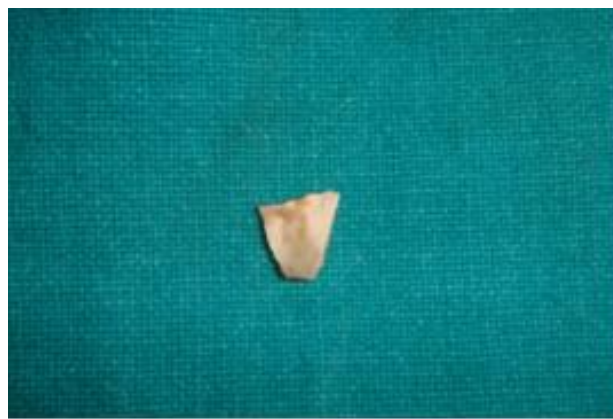

**Figure 1: Preoperative photograph showing subgingival crown fracture (Ellis class III)**

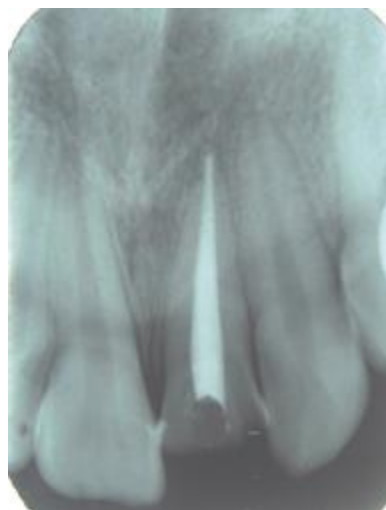
Clinical examination showed the subgingival complicated fracture of permanent left central incisor. The fracture was in horizontal fashion exposing the pulp chamber (Ellis Class III) (fig. 1). The tooth was not mobile and the surrounding structures showed no disturbance. The tooth fragment was retained attached to the tooth only with the support of soft tissue.



**Figure 2: Diagnostic IOPA showing crown fractured tooth with pulp involvement n root intact**



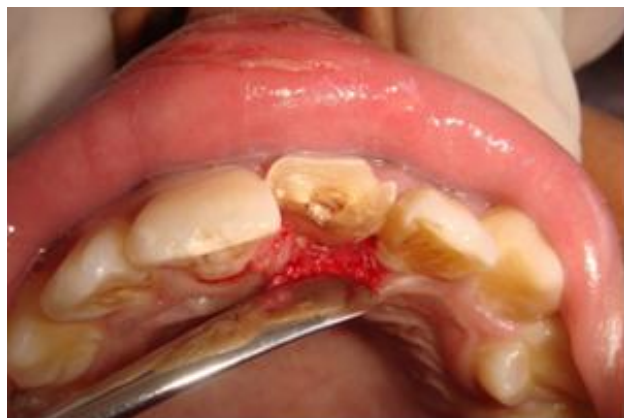**Figure 3: Preserved fractured fragment**



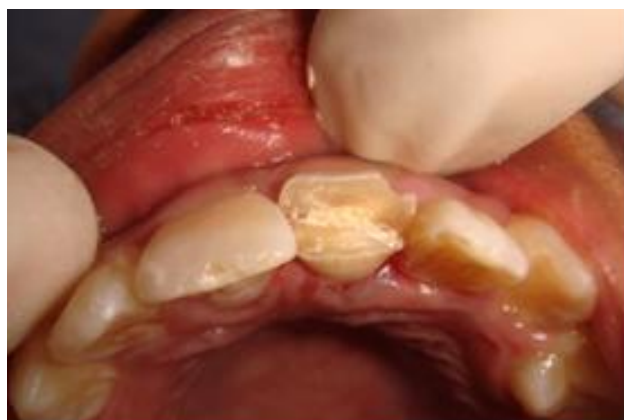**Figure 4: Obturation of fractured tooth (IOPA)**

The radiographic examination revealed that the root of the traumatized tooth was completely formed. The periodontal space was slightly widened. There was no peri apical pathology observed (figure 2). The subgingival fracture

was extending till cemento-enamel junction. Electrical pulp testing displayed a positive pulp response.



**Figure 5: Palatal flap reflected under local anesthesia.**

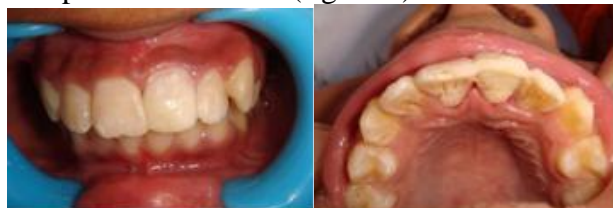

**Figure 6: Fragment reattached using flowable Compomer restorative cement**

At first visit, after administering the local anesthesia the fractured fragment was removed (figure 3). The fragment was cleaned with normal saline and stored in the same. The pulp was extirpated followed by thorough irrigation. Preceding the bio-mechanical preparation the canal was obturated with gutta-percha using lateral condensation technique (figure 4). The access cavity was restored with glass-ionomer cement restoration taking care not to interfere with the fragment reattachment.

The palatal flap was raised (figure 5). The stored fragment and the antagonal palatal surface of the tooth was acid etched with 32% phosphoric acid for 20 seconds. The bonding

agent was applied to the tooth surface and then the fragment was reattached using flowable Compomer restorative cement (figure 6). The rest of the tooth portion was restored with composite restoration (figure 7).



**Figure 7: Tooth restored with composite restoration**

On further follow-ups of one, two & six months, the tooth was asymptomatic with favorable outcome such as proper gingival contour palatally with satisfaction of the patient and the parents psychologically, esthetically and functionally.

### **Discussion:**

The treatment of tooth fractures extending below the gingival margin always led dentist to the questionable treatment planning. The alternative treatment options are composite restorations, post & core and full coverage crown restorations. Sometimes even the crown lengthening procedure or the extrusion of the tooth orthodontically is advised compromising the root length and further problems.<sup>7</sup>

The composite resin has a favorable subgingival reaction and the formation of junctional epithelium and connective tissue adjacent to subgingival restorative materials in humans.<sup>8, 9</sup> But at the same time considering the proper contour and marginal adaptation of subgingival restoration is of prime importance, fragment reattachment serves the purpose up to maximum of its originality. Bonding of original fragment permits subgingival healing with long thick functional epithelium.<sup>10</sup>

In such cases, the conventional treatment plan includes post and core followed by full coverage acrylic crown restoration. However this would be an interim restoration as clinical crown

length and complete occlusion were not yet established.

As a result of changing position of gingival margin, tooth preparation would need to be modified at later stage when it would require a final/ceramic crown restoration. This would mean additional tooth preparation and loss of remaining healthy tooth structure. Also at the time of removal of old acrylic crown, there are possible chances of failure in the form of breakage which would complicate the final treatment planning.

In such a situation, another viable option is fragment reattachment which also serves the purpose of interim restoration with out any tooth reduction. Such type of restoration provides the possible bulk of the tooth material for final restoration at later stage.

This procedure is done in a single visit so less time consuming and more convenient compared to rest of the alternatives.

The fracture of a tooth may be a most traumatic incident for young children, but it has been found that there is a positive emotional and social response from the patient to the preservation of natural tooth structure.<sup>11</sup> The patient walks back home with all function and esthetics restored to its normal level in a single visit which indirectly restores the child's depressed state after a tooth fracture.

#### **Conclusion:**

This case report suggests the possible alternative to full coverage acrylic crown as an interim restoration. Time and material cost is saved utilizing such type of treatment modality along with patients and parents satisfaction. Increasing the awareness about this modality of treatment will be helpful for all patients, parents and dentist.

#### **References:**

1. Andreasen JO, Andreasen FM. Textbook and color atlas of traumatic injuries to the teeth Munksgaard, Copenhagen, 1993.
2. Cohen S, Burns R. Pathways of the Pulp Mosby St. Louis, 1994.
3. Starkey PE. Reattachment of a fractured fragment to a tooth. J Ind Dent Assoc 1979;58:37-8.
4. Simonsen RJ. Restoration of a fractured central incisor using original teeth. J Am Dent Assoc 1982;105:646-8.
5. Damle SG. Textbook of pediatric dentistry. 2nd Ed. Arya PublishingHouse 2002. p. 331-2.
6. Murchison D.F, Burke F.J.T, Worthington R.B. Incisal edge reattachment: indications for use and clinical technique. BDJ 1999; 12:186.
7. Multidiciplinary treatment of complicated subgingivally fractured permanent central incisors: two case reports, Dental Traumatology 2008; 24.
8. Drago MR. Resin-ionomer and hybrid-ionomer cements. 2.Human clinical and histologic wound healing responses in specific periodontal lesions. Int J Periodontics Restorative Dent 1997;17:75-87.
9. Martens LC, Beyls HMF, De Craene LG. Reattachment of the original fragment after vertical crown fracture of a permanent central incisor. J Pedod 1988;13:53-62.
10. Andreasen JO, Andreasen FM. Essentials of traumatic Injures to the teeth, 1st edn. Copenhagen: Blackwell Munsksgaard; 1994. p. 28-35.
11. Baratieri L.N., Monteiro S.: Tooth fracture reattachment: Case reports. Quint Int 1990;21:261-270.

Source of Support: Nil

Conflict of Interest: Not Declared